



PATIENT

Jubilee Forest

SPECIES

Feline

BREED

DSH

SEX

Female Spayed

AGE

10 years

WEIGHT

8.8lbs

INTERPRETED BY

Maggie Machen Lamy,
 DVM DACVIM
 (Cardiology)

IMAGING PERFORMED BY

Crystal Hill, RVT

HOSPITAL NAME

Juno Veterinary
 Burlington

REFERRING VET

Dr. Sterns

INVOICE

47115

DATE

3/5/26

PRESENTING CLINICAL SIGNS

History: Irregular rhythm with intermittent tachycardia runs. Dropped beats. Intermittent gallop and a grade 2/6 parasternal heart murmur noted. Sedated with gabapentin. Assess prior to dental.

ECHOCARDIOGRAM FINDINGS

2D, m-mode, color flow and doppler imaging is available. The left ventricular wall is normal in dimension. There is a mildly hyperechoic endocardium consistent with age-related fibrosis. Mild remodeling. The papillary muscles are hyperechoic yet normal in size. The left atrium is normal in size. The right atrium is normal in size. The right ventricle appears normal. The mitral valve is normal in structure and mobility. No MR or SAM identified. The tricuspid valve appears normal in structure and mobility. No TR. Blood flow through both the LVOT and RVOT are normal in velocity. No AI/PI seen. No effusions. No obvious cardiac tumors. Arrythmia noted.

CARDIAC CHART

| FELINE CARDIAC PARAMETERS | BODY WEIGHT (kg) | HR (BPM) | IVSd (cm) (Moise, Pipers) | LVIDd (cm) (Moise, Pipers) | LVWd (cm) (Moise, Pipers) | FS (%) | EF (%) |
|---------------------------|------------------|---------------------------------|--|----------------------------|---------------------------|----------------|-------------|
| NORMAL PARAMETER | ----- | 150-240 | 0.35-0.55 | <2 (mean 1.5) | 3.5-0.55 | 35-67 | 80-100 |
| PATIENT | 4.0 | 130 | 0.48 | 1.6 | 0.48 | 47 | 90 |
| FELINE CARDIAC PARAMETERS | LA/AO (Boon) | LA/AO HEART BASE (Swe) (Abbott) | LA 2D short axis Base view (cm) (Abbott) | | LVOT VEL (m/s) | RVOT VEL (m/s) | E max (m/s) |
| NORMAL | <1.5 | <1.3 | <1.2 | | <1.6 | <1.3 | <0.9 |
| PATIENT | NM | 1.3 | 1.2 | | 0.8 | 1.0 | NM |

**Note: All measurements based upon multi-modal images and methods. An average value is reported.*
 Adapted from June Boon, Veterinary Echocardiography, 1998
 Abbott J & MacLean H JVIM 2006;20: 111-119, Moise et al. Am J Vet Res 47:1476, 1986. Pipers et al. Am J Vet Res 40:882, 1979.

INTERPRETATION OF THE FINDINGS & FURTHER RECOMMENDATIONS

Overtly normal cardiac structure and function. Mild fibrosis of the left ventricular wall is noted, which is likely a normal age-related variant. No significant valve leaks are noted, and flow through the great vessels is normal in velocity. No definitive cause for the murmur is identified in this study, making it likely physiologic in origin (i.e. secondary to tachycardia, volume changes, etc.). The noted arrythmia is apparent throughout the study. An ECG should be obtained as no further comment can be made.

Given these findings and a normal LA dimension, no medications are indicated. Prognosis is open.

Anesthesia is not advised prior to ECG assessment. No cardiac contraindication for a structural standpoint.



PATIENT

Jubilee Forest

Monitor at home for signs of cardiac compromise, including respiratory changes and/or signs of a blood clot event (paralysis, neurologic changes).

SPECIES

Feline

PLAN

Baseline BP and T4 is recommended. ECG should be assessed.

BREED

DSH

Recommend recheck echocardiogram in 6-12 months.

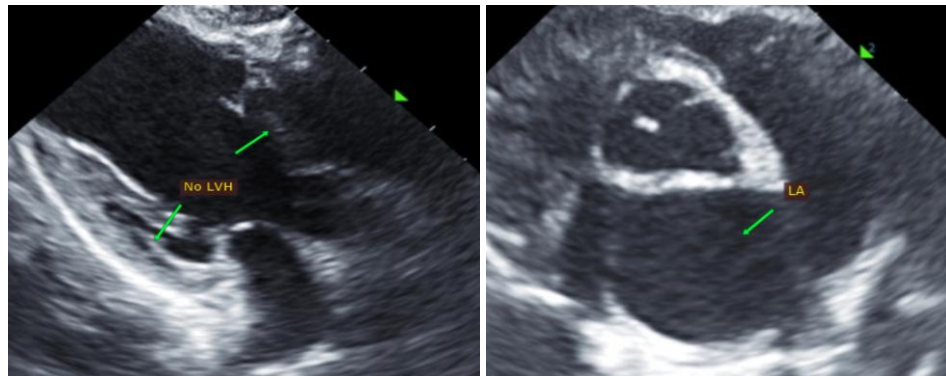
SEX

Female Spayed

IMAGES

AGE

10 years



WEIGHT

8.8lbs

The information and recommendations provided are based on the images presented by the referring veterinarian. No evaluation can be communicated regarding pathology that was not visible in the image/video clips provided.

INTERPRETED BY

Maggie Machen Lamy,
DVM DACVIM
(Cardiology)

Thank you for this referral. This report was generated using transcription software, and minor dictation errors may be present. If the clinical or image interpretation does not parallel your findings or if I can be of any further assistance, please contact me.

IMAGING PERFORMED BY

Crystal Hill, RVT

Maggie Machen Lamy, DVM
Diplomate of the American College of Veterinary Internal Medicine (Cardiology)
info@sonopath.com

HOSPITAL NAME

Juno Veterinary
Burlington

REFERRING VET

Dr. Sterns

INVOICE

47115

DATE

3/5/26